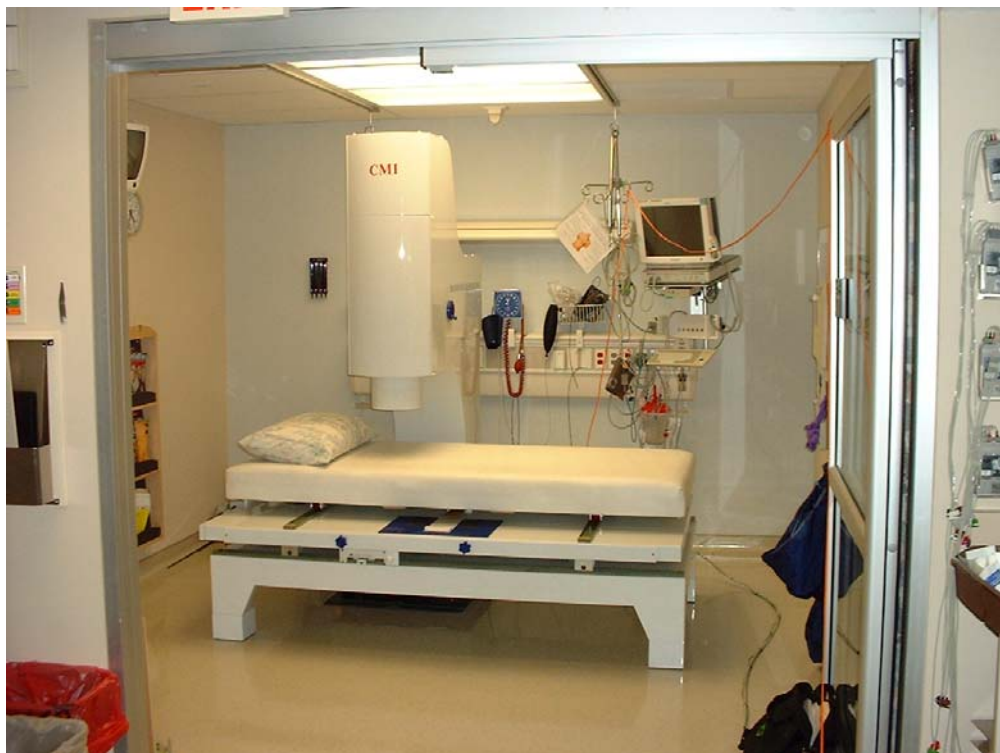

Magnetocardiography

for

Heart-Health Scanning



CardioMag Imaging, Inc.



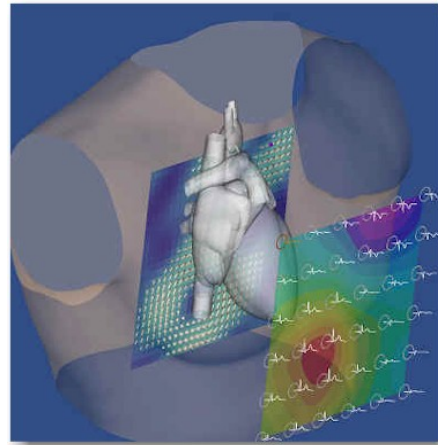
Basic Principles of Magnetocardiography (MCG)

The cardiac electric activity that produces a voltage difference on the body surface (resulting in the ECG trace) produces simultaneously a magnetic field that extends outside the body (resulting in an MCG trace).

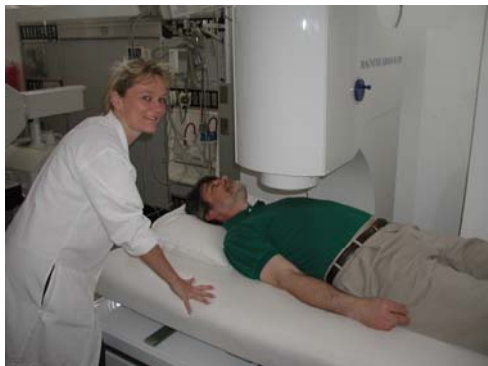MCG signals, unlike ECG signals, are not attenuated by surrounding anatomical structures, tissue, and body fluids, thereby providing more accurate information

Vortex currents in the myocardium produce magnetic signatures that are not visible on the ECG, thereby MCG provides more information.

The MCG is a non-invasive electrophysiological mapping technique that provides unprecedented insight into the generation, localization, and dynamic behavior of electric current in the heart.



Unique Advantages of Magnetocardiography



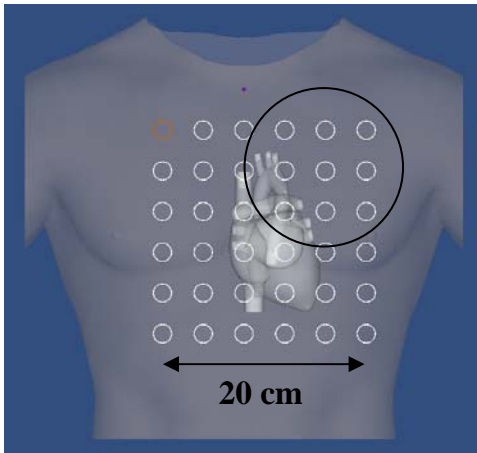
MCG is also being used for...
Non-invasive localization of sources of arrhythmia,
Diagnosis of fetal cardiac disorders,
Screening patients for ischemic heart disease.

Radiation is not used.
Injections are not needed.
Exercise stress and breath holds are not required.
An MCG exam takes less than 10 minutes.
Results are both qualitative and quantitative.
The frequency of MCG exams is limitless, at the discretion of the treating physician.
MCG results provide new, functional information complimentary to that obtained using CT, MRI, ECHO, and SPECT.

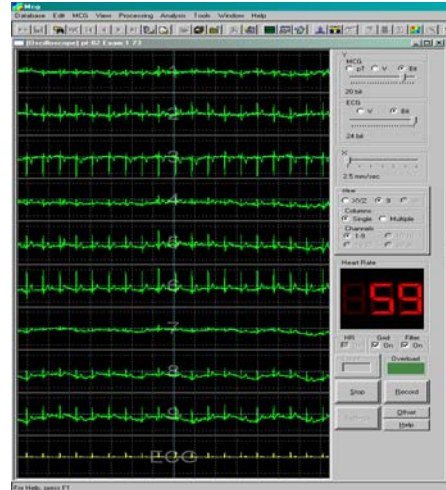
Cost-Benefit Advantages:

Higher confidence diagnoses
More rapid turnaround of emergency department beds
No biohazard waste
Higher throughput scanning
Effective, safe monitoring post-CABG, PCI and PTCA

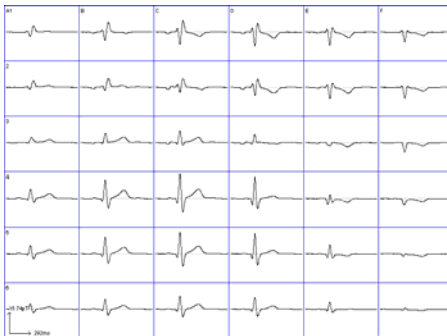
MCG Measurement Sequence



The patient lies comfortably on the table; there is no need to remove clothing. Then the operator lowers the column containing the sensitive magnetic field probes so that it is close to but not touching the patient's chest.



The relative positions of the nine (9) magnetic field probes inside the column are shown as the white circles in the figure above. The outline of the column is in black.

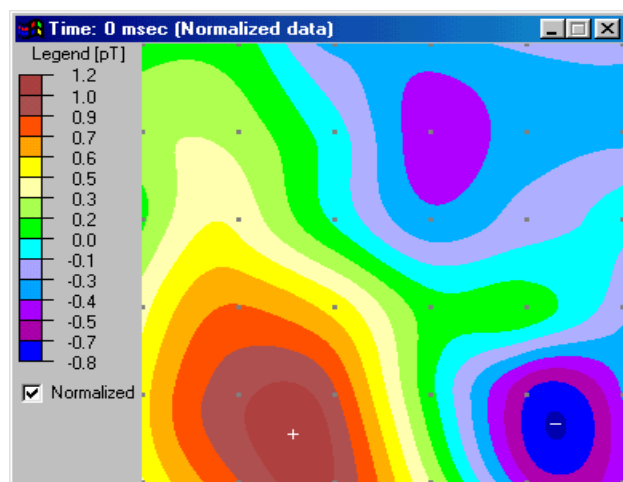


During a measurement, which lasts typically 90 seconds, nine (9) MCG traces and one (1) ECG trace [Lead I] are recorded continuously and displayed on a virtual oscilloscope (as shown above).

The ECG trace is used as a time reference to average the 36 traces of MCG data acquired from four (4) consecutive scans covering a 20cm x 20cm area above the torso.

A representative time-averaged MCG trace at each of the 36 positions is displayed in the 6 x 6 grid to the left.

Interpolation among the 36 points of MCG data (small dots in the color map to the right) and assignment of a color to the strength and direction of the magnetic field yield magnetic field maps which display the electric activity of the heart during the entire cardiac cycle as seen from outside the body.

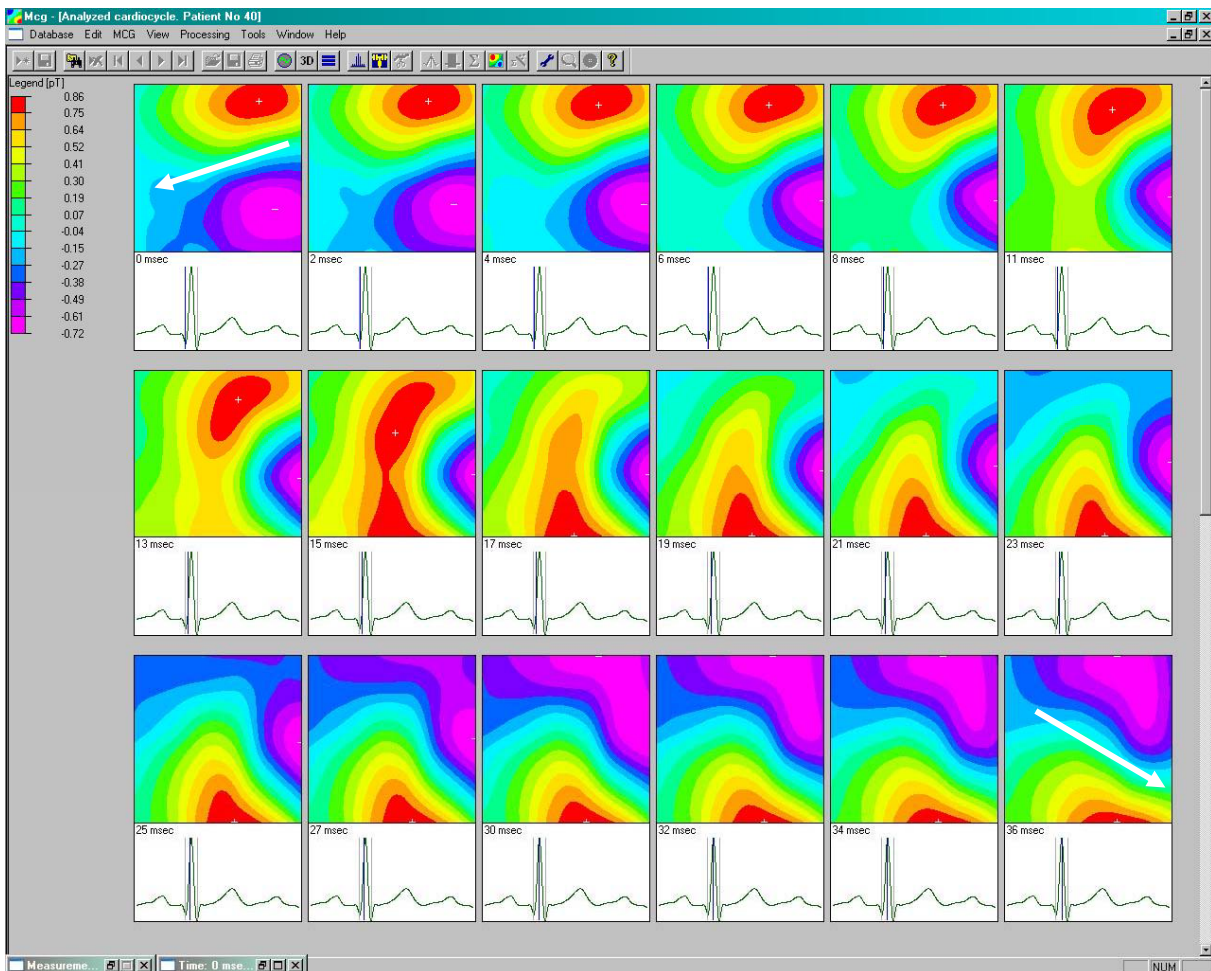


Magnetic Field Maps

Since MCG data are acquired at a frequency of 1 kHz, there are 1000 maps for every cardiac cycle.

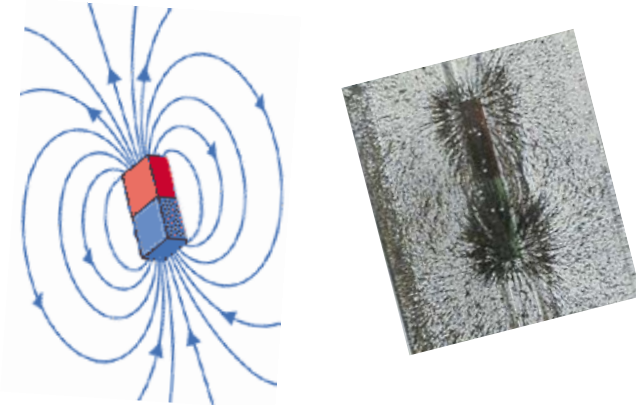
The sequence of 18 maps below shows the dynamics of interventricular septal depolarization, starting with the map at the upper left and proceeding left to right on every line from top to bottom.

Consecutive maps are evenly spaced by a time interval of 2 msec, so that the process shown in the example to the right lasts 34 msec.



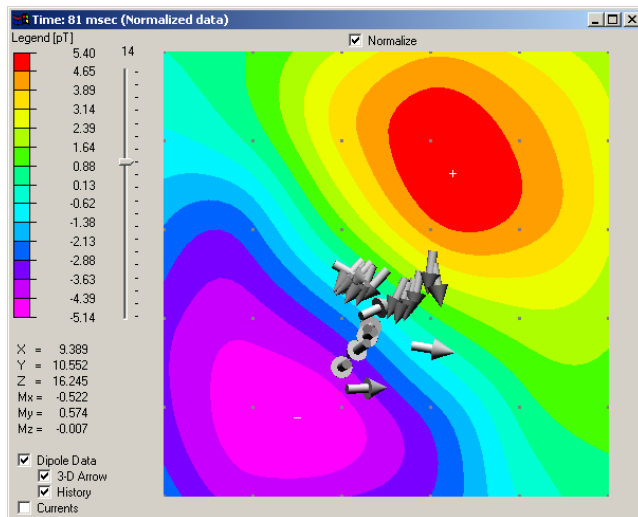
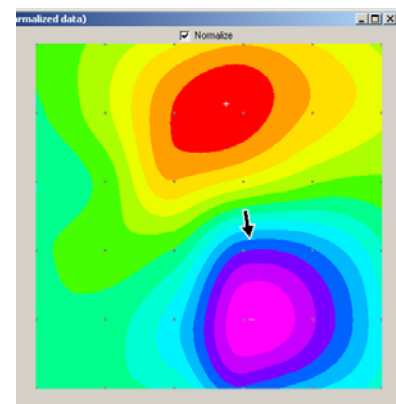
Since effective cardiac electric current flows along the “light blue” line separating the “red” positive field from the “purple” negative field, one can see how the net cardiac current (white arrows above) starts flowing in the interventricular septum from the patient’s left to right, and how it changes as expected, with a final net flow of depolarization current in the direction of the cardiac apex.

Localization and Effective Magnetic Dipoles



The complex magnetic field generated by a simple bar magnet (figure to the far left) is readily visualized by iron filings (as seen in 3D in the figure to the immediate left)

Likewise, the complex magnetic field distribution of the MCG map can be represented by a “virtual bar magnet”, or what is more appropriately named an effective magnetic vector, EMV (shown as a black arrow in the figure to the right). Note that the direction of the corresponding net electric current flow (as described on the opposite page) is perpendicular to this vector.

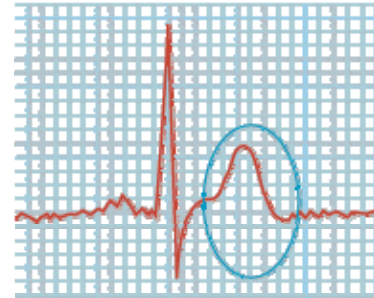


One of the most important problems of biomagnetic investigations is the determination of the coordinates and the magnetic moments for the field sources based on the measured magnetic field. CMI MCG software solves this “inverse problem” and allows the user to track the dipole in space and time over any specified interval in the cardiac cycle.

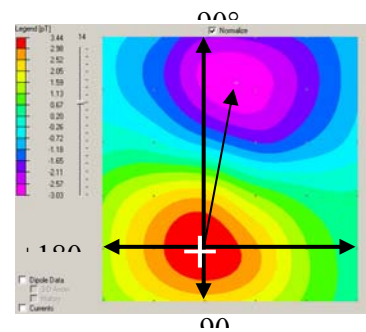
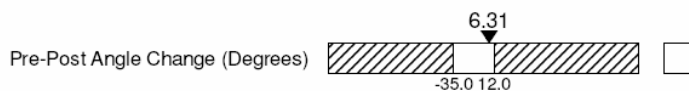
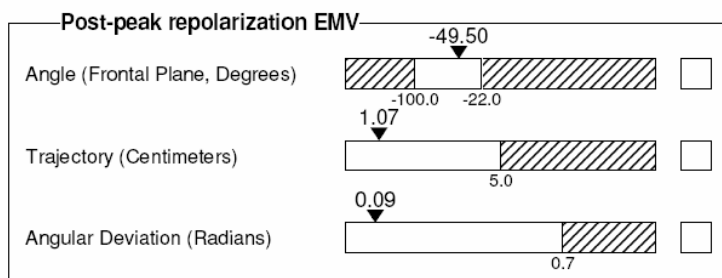
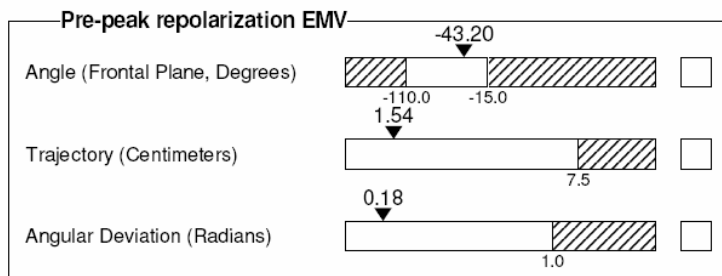
The figure above shows a series of EMV’s representing electrical activity during ventricular repolarization (ascending T-wave). Plotting the EMV path is a unique, useful and much more convenient way to represent the electrical activity over any interval in the cardiac cycle.

Diagnostic Algorithm for Ischemia

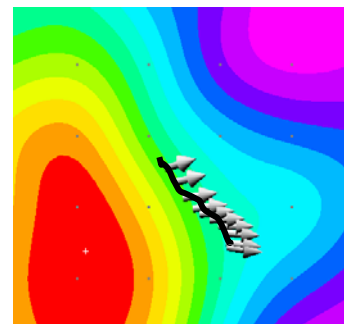
The presence of ischemia is directly related to the direction and dynamic motion of the effective magnetic vector during ventricular repolarization (ascending and descending T-wave) as described by the seven (7) parameters shown in the table below.



Results of EMV analysis

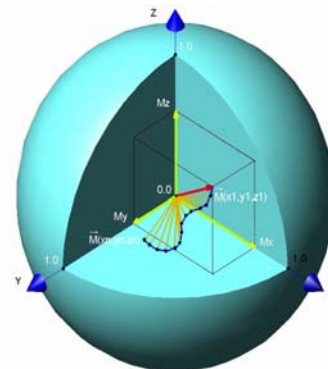


Frontal Plane Angle



Trajectory (black line)

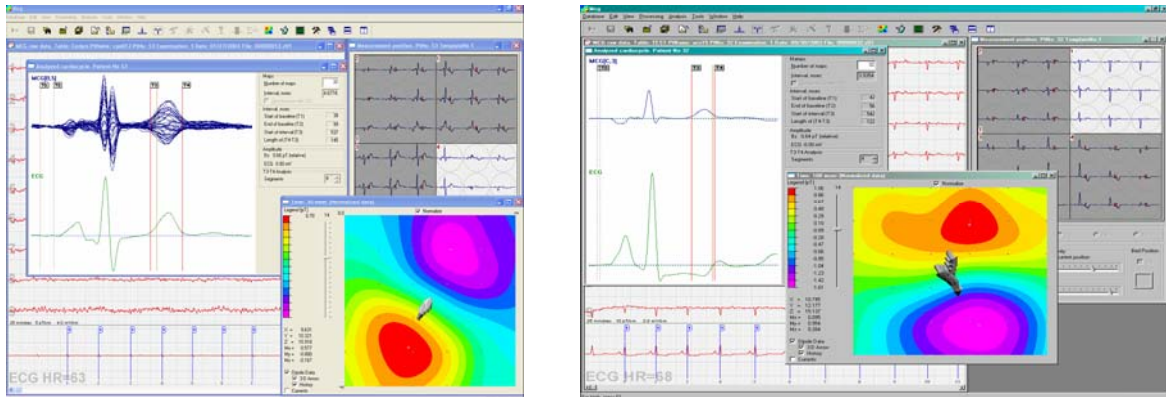
If any of the seven parameters lies in the “shaded” ischemic range, then the patient is considered ischemic. If none of the parameters lies in the ischemic range, the patient is considered not ischemic.



Angular Deviation (blue line)

Diagnosis of Ischemia Using MCG

It is estimated that as many as 8 million Americans present to the emergency department with chest pain or symptoms suggestive of acute cardiac ischemia. Because as many as one-half to two-thirds of those admitted do not have a cardiac cause for their symptoms, the opportunity for improved diagnostics is large.



- ♥ MCG, even in a resting test, provides a rapid, quantitative diagnosis with balanced diagnostic accuracy.
- ♥ MCG traces reinforce conventional methods based on ST segment analysis.
- ♥ Magnetic field maps show the degree of electrical homogeneity and reveal clues about the location of ischemia.
- ♥ Magnetic vector trajectories provide unique insight into abnormal repolarization.

Demonstrated Clinical Value

“Resting magnetocardiographic imaging provides immediate results with very high positive predictive value for obstructive CAD that exceeds or meets the performance of SPECT but without the use of stress provocation, radiation, or injection of nuclear tracer.”

Reference: *Comparison of Resting Magnetocardiography with Stress Single Photon Emission Computed Tomography in Patients with Stable and Unstable Angina*, Tolstrup K. et al., presented at the American College of Cardiology

